Plasmodium falciparum
Blood Stage Parasites, Thick Blood Smears

1: Small trophozoites.
2: Gametocytes — normal.
3: Slightly distorted gametocyte.
4: "Rounded-up" gametocyte.
5: Disintegrated gametocyte.
6: Nucleus of leucocyte.
7: Blood platelets.
8: Cellular remains of young erythrocyte.

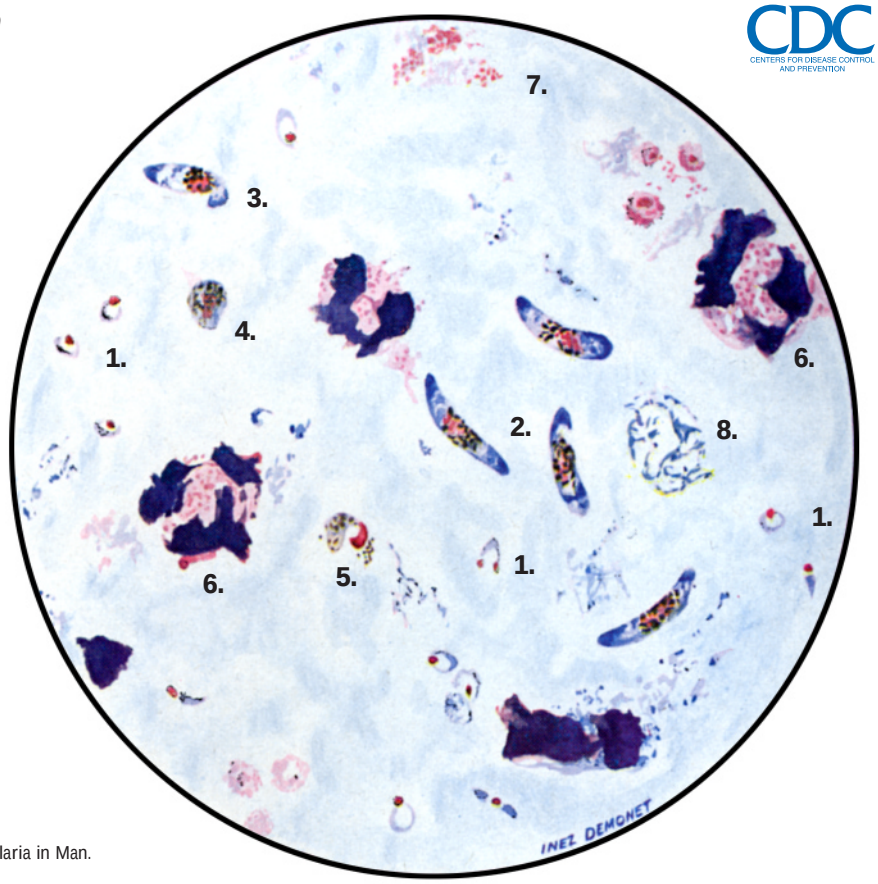

Illustration from: Wilcox A. Manual for the Microscopical Diagnosis of Malaria in Man. U.S. Department of Health, Education and Welfare, Washington, 1960.

Plasmodium malariae
Blood Stage Parasites, Thick Blood Smears

1: Small trophozoites.
2: Growing trophozoites.
3: Mature trophozoites.
4, 5, 6: Immature schizonts with varying numbers of divisions of the chromatin.
7: Mature schizonts.
8: Nucleus of leucocyte.
9: Blood platelets.
10: Cellular remains of young erythrocytes.

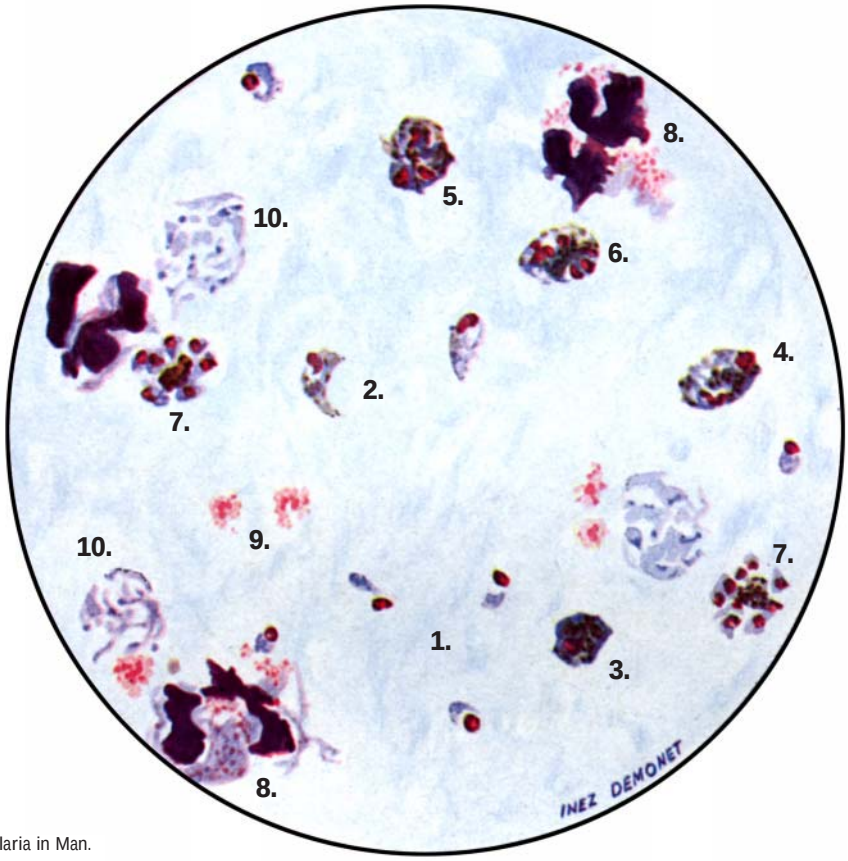

Illustration from: Wilcox A. Manual for the Microscopical Diagnosis of Malaria in Man. U.S. Department of Health, Education and Welfare, Washington, 1960.

Plasmodium ovale
Blood Stage Parasites, Thick Blood Smears

1: Small trophozoites.
2: Growing trophozoites.
3: Mature trophozoites.
4: Schizonts.
5: Gametocytes.
6: Nucleus of leucocyte.
7: Blood platelets.

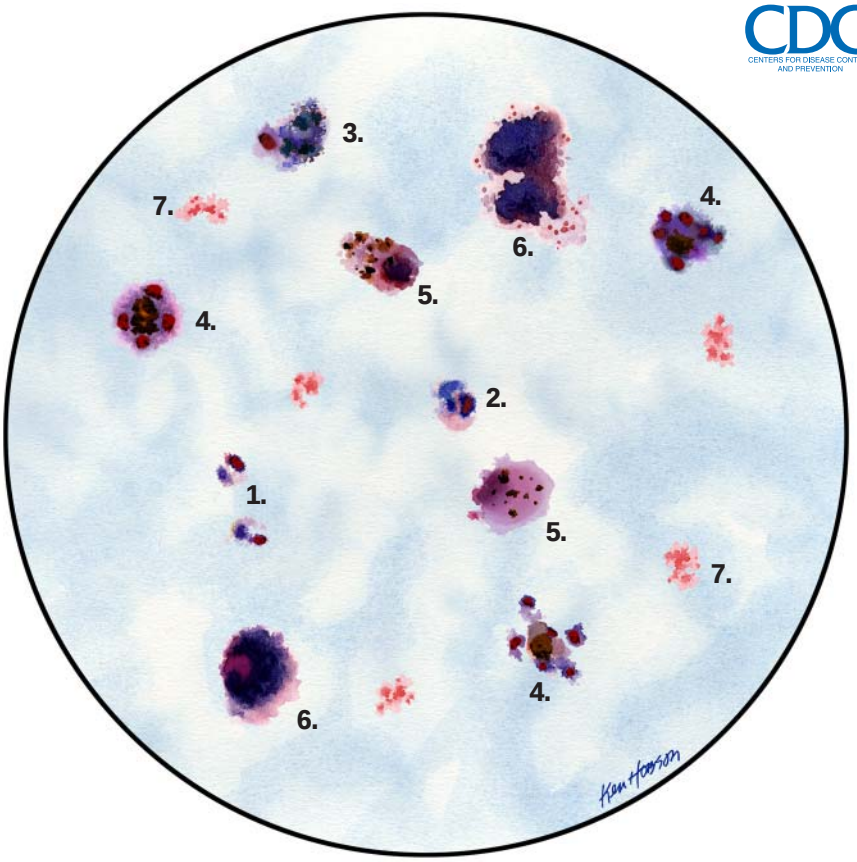

Plasmodium vivax
Blood Stage Parasites, Thick Blood Smears

1: Ameboid trophozoites.
2: Schizont — 2 divisions of chromatin.
3: Mature schizont.
4: Microgametocyte.
5: Blood Platelets.
6: Nucleus of neutrophil.
7: Eosinophil.
8: Blood platelet associated with cellular remains of young erythrocytes.

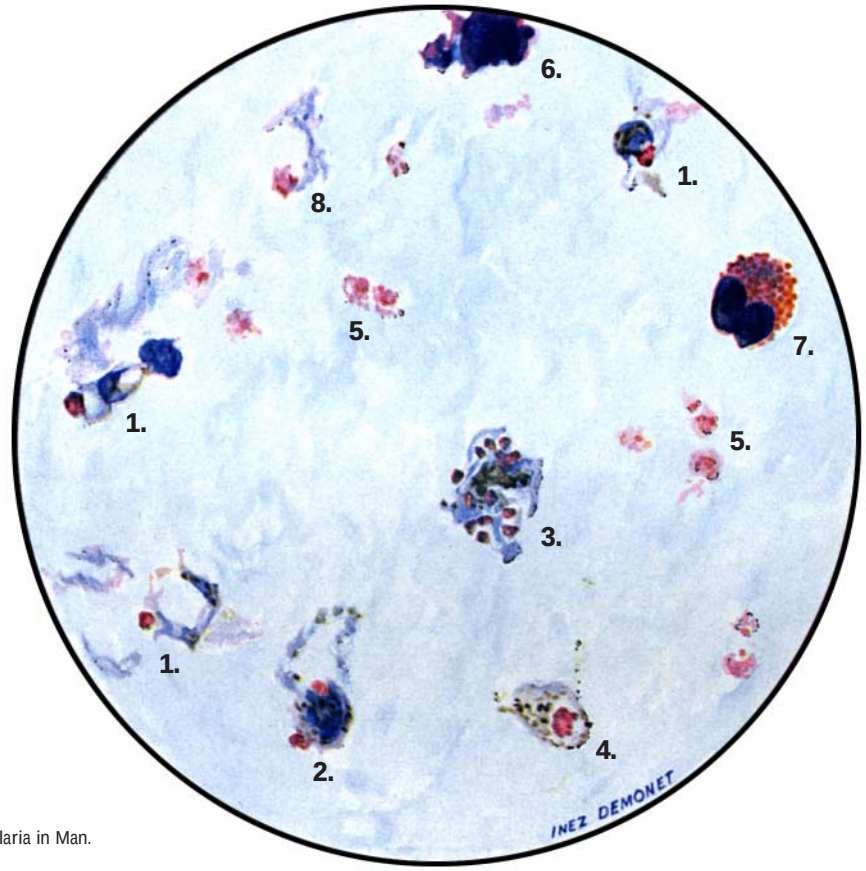

Illustration from: Wilcox A. Manual for the Microscopical Diagnosis of Malaria in Man. U.S. Department of Health, Education and Welfare, Washington, 1960.